

## TEN COMMON SENSE REASONS WHY YOU SHOULD NOT HAVE LASIK

---

After years of dealing with the hassle of spectacles and contact lenses, you've decided to reward yourself by having Lasik. You've read the glowing reports in the media about the wonders of this "state of the art" procedure and your ophthalmologist has just pronounced you "a perfect candidate."

It is at this time, more than at any other time in your life, that you must pause, stand back from the excitement of the moment, and reflect deeply on what you are about to do. Lasik will permanently alter the optics and physiology of your eyes. Most likely things will go well. But there is a significant chance, much greater than many ophthalmologists realize or will publicly admit, that your eyes will be irreversibly damaged. The results could be devastating.

When considering elective surgery one must ask if the benefits truly outweigh the risks involved. You've heard a lot about the benefits, no doubt from the surgeon who stands to gain financially by operating on your eyes. But you owe it to yourself to take a few minutes to read the rest of this document in order to become better informed about the risks of Lasik. Once you understand these risks, you may conclude that the prudent course of action is to avoid the Lasik fad until the procedure has fully matured, withstood the test of time, and been proven safe. After all, we're talking about your eyes.

### 1. The True Degree of Risk is Unclear and is Being Downplayed.

Before surgery, patients are typically told that the risk of complications from Lasik is 1%, and even lower in the hands of an experienced surgeon (such as the one trying to sell you the procedure). For starters, one must realize that the risk being referred to is for *each* eye, so the combined risk that permanent damage will occur to at least one eye is, by these figures, actually 2%. Doesn't sound so good anymore? Read on...

At the 1997 Association for Research in Vision and Ophthalmology meeting in Fort Lauderdale, Florida, researchers reported that up to 21% of patients who undergo laser correction complain of night-vision problems stemming from reduced contrast sensitivity, glare, and halos.<sup>1</sup>

According to another study, at one year postoperatively 12% of Lasik patients complained of visual disturbances at night. The figure for PRK patients was, by comparison, "only" 6%.<sup>2</sup>

During the process of obtaining Food and Drug Administration (FDA) Preliminary Market Approval (PMA) for its LADARVision Excimer Laser System, Alcon Corporation admitted that 22.8% of Lasik patients complained of light sensitivity post-operatively, 7.1% now suffered from headaches, 31.9% had glare symptoms, and 32% now

---

<sup>1</sup> See James J. Salz, M.D., *Night Vision and the Excimer Laser: How to Ensure Patient Satisfaction*, EYEWORLD, Nov. 1997.

<sup>2</sup> PRK, *Lasik, Neck and Neck in Controlled, Matched Study*, OPHTH TIMES, Feb 15, 1999.

experienced night driving difficulties.<sup>3</sup> The FDA nevertheless approved the LADARVision laser for commercial use,<sup>4</sup> once again giving more weight to the interests of industry than to the public's welfare. This occurred despite the fact that 12.7% of LADARVision patients stated that they experienced "worse" or "significantly worse" quality of vision, as reported in the PMA.<sup>5</sup>

A study presented in the *Review of Optometry*<sup>6</sup> summarized surgical (as opposed to optical) complication rates following Lasik as follows:

Interoperative Flap Complications	-	2.7%
Postoperative Flap Complications	-	4.0%
Epithelial Ingrowth (Farah)	-	14.7%
Epithelial Ingrowth (Wilson)	-	4.3%
Epithelial Defects	-	5.0%
Interface Debris	-	6.8%
Flap Wrinkles	-	5.9%

These complications often produce vision-distorting irregular astigmatism. Unlike regular astigmatism, which is correctable with glasses, irregular astigmatism cannot be corrected with glasses. Rigid Gas Permeable (RGP) contact lenses offer some hope to those suffering from Lasik-Induced Irregular Astigmatism (LIIA) because they provide a smooth surface that masks corneal irregularities by permitting pooling of tears beneath the lens. However, due to the flattening of the cornea following Lasik, it is nearly impossible to find RGP

<sup>3</sup> See Premarket Approval Application #P970043/S5, available through Dockets Management Branch (HFA-305), FDA, p.19.

<sup>4</sup> Approved May 9, 2000. See Docket #OOM-1592, p.1.

<sup>5</sup> See Premarket Approval Application, p. 23.

<sup>6</sup> See Paul M. Karpecki, O.D. and Steven Linn, O.D., *What You Should Look for When Lasik Goes Astray*, REV OPTOMETRY, May 1999.

lenses that will stay centered over the pupil and that will not rub against the interface between treated and untreated areas of the cornea. The result is that RGP lenses are extremely uncomfortable for the post-refractive and therefore do not offer a viable solution to irregular astigmatism. New laser techniques involving eye tracking are being developed to treat irregular astigmatism,<sup>7</sup> but they are still in the experimental stages, are yielding mixed results, and may never be precise enough to correct LIIA.

Many ophthalmologists remain in willful ignorance of Lasik's true risks, often preferring to avoid patients with post-Lasik complications because it is much less profitable to treat such a patient than to operate on a fresh candidate. These doctors therefore never gain an accurate awareness of the extent of damage that is being done by Lasik. Their ignorance is compounded by their unfamiliarity with organizations such as SurgicalEyes.Com and LasikInfoCenter.Net, which are dedicated to providing emotional and informational support to thousands of

<sup>7</sup> These include Alcon-Summit-Autonomous/Zeiss's CustomCornea System, Visx's WaveScan Wavefront Analysis System based on Hartmann-Shack principles, Bausch & Lomb's Zyoptix System, the University of Dresden's Wavefront Analyzer, Tracey Technologies' Visual Function Analyzer, Wavefront Sciences/Asclepion-Meditec's Complete Ophthalmic Aberrometer System, Nidek's Optical Path Difference Retinoscopy-Based System, and Laser Sight Technologies' CustomEyes System. All of these systems are still in clinical trials. See Michael Moretti, *Laser Makers Riding the Wavefront in Corneal Ablation Push*, BBI NEWSLETTER, No. 2, Vol. 24, p.41, Feb. 1, 2001.

people suffering from refractive surgery complications.<sup>8</sup>

## 2. Lasik Technology is in its Infancy.

The refractive surgical community depends financially on the average individual's tendency to get swept up by fads. This natural human tendency provides refractive surgeons and medical device manufacturers with large numbers of patients on whom to refine their surgical techniques and devices.

At present, for example, there is no consensus on what kind of excimer laser provides optimal results. Nidek's single beam laser follows a very different approach to ablating corneal tissue from that of Visx's broad beam laser, yet both are touted as being "state of the art." Many surgeons cut the Lasik flap from side to side with the Chiron microkeratome, while other surgeons pronounce themselves experts in using the Hansatome microkeratome, which cuts a supposedly superior "up-down" flap.<sup>9</sup>

<sup>8</sup> Surgicaleyes.org receives tens of thousands of postings monthly from people with post-surgical complications, a fact that belies any claims that refractive surgery is "safe."

<sup>9</sup> Despite the Hansatome's supposed superiority, a recent study concluded that it does not always produce a corneal flap of the intended thickness. Flaps that are too thin can lead to flap wrinkles, which in turn cause devastating irregular astigmatism. See Rengin Yildirim, M.D. *et al*, *Reproducibility of Corneal Flap Thickness in LASIK Using the Hansatome Microkeratome*, J CATARACT REFRACT SURG (2000) 26: 1729-32. See also Vikram D. Durairaj, M.D. *et al*, *Predictability of Corneal Flap Thickness and Tissue Laser Ablation in LASIK*, OPTH (2000) 107: 2140-43 ("Actual flap thickness was significantly different from predicted flap thickness.").

The field of refractive surgery is still so new that many ophthalmologists develop and market their own surgical instruments to perform various procedures, such as cutting, lifting, or irrigating flaps. Perhaps some of their enthusiasm for Lasik stems from the goal of "creating rapid profits by promulgating sales of surgical equipment and adopting new surgical techniques," as one eminent refractive surgeon has speculated.<sup>10</sup>

Marketers recognize a type of consumer known as the "early adopter," who enjoys buying the latest products and technology. Refractive surgeons are also keenly aware of this, and most medical texts about refractive surgery contain one or more chapters on how to boost profits by targeting such consumers. The discussion of marketing strategies in medical texts is remarkable in and of itself, and speaks volumes about the commercial nature of this field of "medicine."

There is no harm in being an early adopter when one is dealing with a video game or laptop computer. But does this approach make sense with an irreversible surgical procedure on one's eyes? Dr. George Waring, Editor-in-Chief of the *Journal of Refractive Surgery*, answers this question best when he writes that "...we proceed with active teaching of hundreds or thousands of

<sup>10</sup> See George O. Waring III, MD, FRCOphth, *A Cautionary Tale of Innovation in Refractive Surgery*, ARCH OPTH, Vol. 117, No. 8, Aug. 1999. Dr. Waring has stated that he would not be willing to take even a 1 in 500,000 risk on his own eyes through elective refractive surgery. See Jeffrey Weiss, *Demand High for RK Eye Surgery -- Critics Say Glasses, Contacts Work Best, Doctors Just Trying to Enrich Themselves*, SEATTLE TIMES, July 12, 1993, at A4.

ophthalmologists to use a technique that we are simultaneously figuring out how to do -- including the identification of complications and statistical outcomes. Is it not safer for patients and more rational for the profession to proceed in a graduated manner, refining the techniques and improving the results on smaller numbers of patients (or in the laboratory), and saving our mass education for the time when we have worked the bugs out of the technique and have acquired reasonably quantitative descriptions of safety and efficacy?"<sup>11</sup>

Other leading refractive surgeons concur that the Lasik procedure has not yet been perfected. One group writes that "As the technology and techniques improve, we should develop a better understanding of the importance of laser-tissue interactions, corneal wound healing, and the role of pharmacologic agents in modulating refractive outcomes. These advances should allow PRK and LASIK to become more predictable with fewer complications."<sup>12</sup>

Do you want your eyes to be the ones to help these doctors learn how to perform Lasik more safely and successfully?

### **3. Lasik Induces Optical Aberrations that are Poorly Understood by Ophthalmologists.**

Refractive surgery tries to eliminate spherical and cylindrical defocus, the

most important optical aberrations. However, this approach ignores the fact that the eye has significant higher-order aberrations. According to Dr. Raymond Applegate of the Department of Ophthalmology of the University of Texas Health Science Center, these naturally occurring higher-order aberrations, combined with large increases in the eye's higher-order aberrations induced by refractive surgery, can decrease visual performance despite the elimination of spherocylindrical errors. Surgically-induced higher-order aberrations have received less attention than the correction of defocus errors despite their importance to optimal visual performance.<sup>13</sup>

Moreover, the normal cornea is relatively trouble-free whereas the post-refractive cornea frequently has a more aberrated optical performance. It is often unstable and its optical performance deteriorates at night or in patients with larger-than-average pupils. Contact lenses and spectacles do not permanently alter the physiologic optics of the eye. Refractive surgery does. According to Dr. Leo Maguire of the Mayo Clinic, "When one alters irreversibly the most trouble-free component of the human visual system, one runs the risk of compounding the visual aberration caused by components of the visual system that characteristically show dysfunction with age (the lens and macula)."<sup>14</sup> Dr. Maguire worries about how many refractive patients who can

<sup>11</sup> George O. Waring, III, MD, FACS, FRCOphth, *Editorial*, J REFRACT SURG, Vol. 12, No. 3, Mar./Apr. 1996.

<sup>12</sup> Edward E. Manche, Jonathan D. Carr, Weldon W. Haw, and Peter S. Hersh, *Excimer Laser Refractive Surgery*, WESTERN J MED, Jul. 1, 1998, Vol. 169, No.1.

<sup>13</sup> See Raymond A. Applegate, OD, PhD & Howard Howland, PhD, *Refractive Surgery, Optical Aberrations, and Visual Performance*, J REFRACT SURG, Vol. 13, May/June. 1997.

<sup>14</sup> See Leo J. Maguire, Mayo Clinic, *Keratorefractive Surgery, Success, and the Public Health*, AM J OPHTH, Vol. 117, No. 3, March 1994.

compensate for their aberrated cornea will be able to do so when the lens and macula develop age-related changes. How much sooner will they require cataract surgery or visual aids for macular degeneration?<sup>15</sup>

Another reason why the eye's optics are degraded by Lasik is that excimer lasers were designed by engineers who assumed that the cornea is spherical rather than prolate.<sup>16</sup> According to Dr. Jack Holladay, McNeese Professor of Ophthalmology at the University of Texas Medical School, these engineers further assumed that their job was to reshape a steep sphere into a flat sphere, rather than to reshape a steep prolate into a flatter prolate. As a result, excimer lasers reshape prolate corneas into oblate ones, a shape that is optically worse because now peripheral rays are bent more powerfully, causing more pronounced spherical aberrations when the pupil dilates. This problem to some extent affects every patient who undergoes an excimer laser procedure.<sup>17</sup>

A final optical ramification of Lasik that is poorly understood by most ophthalmologists is that following Lasik the eyes must focus and converge entirely unaided. However, after years of adaptation to the prismatic effect of myopia-correcting glasses, many eyes will have difficulty working together. This problem of visual fusion can be compounded if either eye experiences even a slight decrease in vision due to a post-Lasik complication. If the eyes are

<sup>15</sup> *See id.*

<sup>16</sup> The normal cornea is prolate, which means that it is steepest in the center and gets gradually flatter in the periphery. An oblate cornea is flatter in the center than the normal cornea.

<sup>17</sup> See Jack Holladay, MD, MSEE, FACS, *What We Should Really Tell Lasik Patients*, REV OPHTH, May 1999.

unable to adapt after Lasik, the post-refractive patient will have difficulty reading and will experience constant eye strain.

Dr. Holladay concludes by writing that "We are actually ruining the optics of the eye when we perform Lasik. That's fine when the pupil is small, but as it gets larger, such as in nighttime conditions, this becomes a problem."<sup>18</sup>

#### 4. Lasik Reduces Contrast Sensitivity.

Most people will never know what contrast sensitivity is unless they lose it as the result of Lasik. An example of diminished contrast sensitivity is that someone who is walking towards you in a situation where he is lit from behind appears as a dark silhouette. Pre-Lasik his facial features would have been easily identifiable. Seeing a white rabbit against the snow also becomes more difficult. Loss of contrast sensitivity is permanent and to varying degrees affects everybody who undergoes Lasik.

A recent study performed for the London Centre for Refractive Surgery following up on patients two to seven years after refractive surgery determined that 58% failed a contrast sensitivity test for night driving.<sup>19</sup> These results have been supported by another study at Germany's Tübingen University, where more than 70% of post-refractives failed a night vision test -- a requirement

<sup>18</sup> *Eye on Technology: New Procedure, Product Refines Lasik*, INTL SOC REFRACT SURG - EYE2EYE, Jul. 2000, p. 6.

<sup>19</sup> See Carol Hilton, *Studies Show Compromised Night Vision an Undetected Complication of Laser Eye Surgery*, THE MED POST, Jun. 6, 2000 (citing research performed by Dr. William Jory, Consultant Surgeon for the London Centre for Refractive Surgery).

in Germany for receiving a driver's license.<sup>20</sup> The U.K. Transportation Research Laboratory has concluded that due to loss of contrast sensitivity, at night 80% of post-refractives can't see a traffic sign at 55 meters, and 40% still can't see the sign at 15 meters.<sup>21</sup> The Canadian Medical Association has added laser eye surgery to a list of risk factors for unsafe driving, after finding a decrease of night vision in between 30 and 60% of laser eye patients.<sup>22</sup>

Why does this happen? One hypothesis is that some of the laser's energy goes beneath the targeted ablation to the corneal stroma and disturbs the fibrils.<sup>23</sup> However, there are other hypotheses and no clear answers.

Perhaps you are wondering why this side effect of Lasik has gone largely unnoticed in the United States. The reason is that, although contrast sensitivity tests are easy to administer both pre- and post-operatively, they consume more time than most ophthalmologists are willing to spend with their patients. If refractive surgeons were to take the time to perform all the recommended diagnostic tests, they would be spending several hours with each patient and the procedure would quickly become uneconomical for them. Therefore, they generally only spend about one or two hours giving their patients a stripped-down pre-operative evaluation. Issues such as the effect of

<sup>20</sup> See Louise Elliott, *Canadian Medical Association Says Laser Eye Surgery Can Pose Driving Risk*, CANADIAN PRESS, Aug. 27, 2000.

<sup>21</sup> See *id.*

<sup>22</sup> See *id.*

<sup>23</sup> See *id.* See also, Maxine Lipner, *Inside Lasik -- First on the Endothelial Cell Block*, EYEWORLD, Sep. 2000. (noting recent studies indicating endothelial cell damage resulting from excimer laser radiation).

Lasik on contrast sensitivity get lost in the rush to put more patients through the Lasik mill.<sup>24</sup>

## 5. Lasik Reduces the Cornea's Structural Stability.

The cornea has a natural tendency to become thinner with age.<sup>25</sup> Combine this with the surgical removal of corneal tissue through Lasik, and there can potentially be serious problems.<sup>26</sup> Recent studies have indicated that people who undergo Lasik are at greater risk of developing Iatrogenic Keratectasia (Ectasia) due to corneal thinning.<sup>27</sup> Ectasia is the weakening of the cornea's structural stability, which causes the cornea to bulge forward, resulting in distorted vision, return of myopia, fluctuating vision, and even more corneal thinning. In the worst cases of ectasia, the only remedy is a full-scale corneal transplant. Even patients with low

<sup>24</sup> This rush to operate is exemplified by a recent advertisement by the Hillside PlusCare Network, directed at refractive surgeons eager to acquire more Lasik patients. It exclaimed, "What do You Feed a Hungry Laser? Patients!"

<sup>25</sup> See AM. ACAD. OPHTH., External Disease and Cornea - Basic and Clinical Science Course, 1998-99, p.338. See also ARCH. OPHTH., *Changes With Age in Normal Cornea*, 1982 (100): 1942.

<sup>26</sup> See George O. Waring III, *The Limits of Keratomileusis*, *Special Article*, ARCH OPHTH, Vol. 117(8), Aug. 1999 (noting that there is no published long-term follow-up on a consecutive series of eyes with a thorough statistical analysis of changes in corneal curvature after Lasik).

<sup>27</sup> See B. Seitz et. al., *Posterior Corneal Curvature Changes After Myopic Lasik*, OPHTH, Vol. 108(4), April 2001, pp. 666-72; T. Baek et. al., *Factors Affecting the Forward Shift of Posterior Corneal Surface After Lasik*, OPHTH, Vol. 108(2), Feb. 2001, pp. 317-20.

degrees of myopia can suffer from Lasik-Induced Ectasia (LIE).<sup>28</sup>

The long-term weakening of the cornea has been well documented in other cases of corneal refractive surgery, including radial keratotomy. Although the mechanism of weakening is different in incisional surgery, it may be even more profound in excisional surgery such as Lasik.<sup>29</sup> Furthermore, the flap that is created in Lasik, though resting on the corneal bed underneath, does not weld to that corneal bed for several years, further reducing the cornea's tensile strength.

Weakening of the cornea following Lasik is poorly understood because no statistically valid scientific studies have been performed. According to one renowned refractive surgeon, "We have failed to ask some fundamental questions about the stability of refraction of the human eye."<sup>30</sup>

## 6. Lasik Often Causes Photophobia.

Photophobia is the painful sensitivity to light that often results from Lasik.

<sup>28</sup> See S. Percy Amoils, Mark Deist, Petrus Gous, Philippa Amoils, *Iatrogenic Keratectasia after Laser In-Situ Keratomileusis for Less Than -4.0 to -7.0 Diopters of Myopia*, J CATARACT REFRACT SURG 2000, Vol. 26, No. 7, Jul. 2000, pp. 967-977.

<sup>29</sup> See Richard E. Damiano, M.D., *Late Onset Regression After Myopic Keratomileusis -- Letter to the Editor*, J REFRACT SURG, Vol. 15, Mar./Apr. 1999. See also Theo Seiler, M.D., *Iatrogenic Keratectasia: Academic Anxiety or Serious Risk?*, J CATARACT REFRACT SURG., Vol. 25, No. 10, Oct. 1999.

<sup>30</sup> See Chris Glenn, REV OPHTH, Apr. 2000 (quoting Dr. Daniel Z. Reinstein, MD, MA, FRCS, Professor of Ophthalmology at the University of Paris, Associate Professor at Cornell University, and National Medical Director for Lasik Vision Corp. of Vancouver, B.C.).

Though the exact causes of post-Lasik photophobia are unknown, some surgeons hypothesize that light scatter and glare resulting from post-Lasik corneal surface irregularities are the culprits. Others believe that low-grade inflammation produced by the Lasik procedure is the true cause of the problem.

Whatever the cause of photophobia following Lasik, the result is that sunglasses become a constant necessity whenever one is outdoors. It is a grim paradox that while people undergo Lasik in order to reduce their dependency on glasses, now many will have increased dependency on sunglasses.

## 7. Myopia Will Eventually Be Your Friend.

Myopia reduces and can even eliminate the need for reading glasses, which compensate for the lens's greater rigidity as we age. This rigidity reduces the lens's ability to accommodate in order to focus on near objects. Thus myopia eventually becomes your friend. In cases of mild myopia, to read you simply remove your glasses or at worst wear bifocals, which are lighter than normal glasses because the reading lens has a lighter prescription than the lens used for distance vision. In cases of more severe myopia, the image minification effect of glasses makes it more comfortable for the eye to see close-up objects. Thus people with high degrees of myopia may never even need bifocals due to the image minification produced by their glasses.

Refractive surgery to eliminate myopia improves distance vision at the expense of near vision. Eliminate the need for glasses by having Lasik at the

age of, say, 30, and within little more than a decade you will start having to deal with the inconvenience of carrying reading glasses with you at all times in order to do any close-up work such as read, use the computer, even see your wristwatch.

## 8. Lasik Increases the Risk of Cataracts

Lasik increases the risk of cataracts in two ways.

First, steroid medications such as Tobradex, Alrex, Pred Forte, and FML, the standard treatments for several post-Lasik complications, have been proven to induce posterior subcapsular cataracts if taken for prolonged periods.<sup>31</sup> Though prolonged use of steroids is usually not necessary following Lasik, there are several complications (e.g., corneal abrasion, infection, haze) that require extended treatment using steroid drops.

Second, the anti-ultraviolet coating that is standard with most eyeglasses provides a constant barrier against the sun's cataract-inducing ultraviolet rays. Eliminate this protective barrier through Lasik and your increased exposure to everyday sunlight will slowly but cumulatively increase your risk for developing cataracts later in life.

## 9. Lasik Causes Drier Eyes.

<sup>31</sup> See PDR OPTH, 1999, p. 244; *Fluorometholone-Induced Cataract After PRK*, OPTHALMOLOGICA 1997, pp. 394-96 (noting the case of a 24-year-old woman who developed cataracts after using FML 4-7 times per day for 4 months); and *Lens & Cataract*, § 11, BASIC & CLINICAL SCIENCE COURSE, AM ACAD OPTH (noting that 50% of patients developed cataracts after receiving 765 drops of topical steroid over 10.5 months).

Post-Lasik Dry Eye (PLDE) is quite common, and its treatment is one of the most difficult problems facing refractive surgeons.<sup>32</sup> For the patient, it is an uncomfortable and often painful condition that persists indefinitely. According to Dr. Paul M. Karpecki, OD, Clinical Director of Cornea and Refractive Surgery for Hunkeler Eye Centers, "Not all patients are affected, but a very high percentage are."<sup>33</sup>

The reason post-Lasik dry eye is so difficult to deal with is that the Lasik procedure disrupts so many facets of the eye's tear production mechanism.

First, insertion of a speculum in order to expose the eye in preparation for surgery disturbs proper eyelid function, creating a medical condition known as logophthalmos. The speculum stretches the eyelids substantially and this stretching can damage the levator complex of the upper lid.<sup>34</sup> This

<sup>32</sup> See Eric Donnenfeld, MD, *At Issue: Tears Versus Plugs in Post-Lasik Patients*, OCULAR SURG NEWS, Jun. 1, 2000. See also *Eye Drops Help in Management of Dry Eye Symptoms*, OPTH TIMES, June 1, 1999 ("Dry eye is a common occurrence following LASIK surgery. Creation of the flap denervates the cornea overlying the flap, and decreased corneal sensation decreases tear production, thereby increasing osmolarity.").

<sup>33</sup> See Eric Donnenfeld, MD, *At Issue: Tears Versus Plugs in Post-Lasik Patients*, OCULAR SURG NEWS, Jun. 1, 2000. See also REV OPT, Feb. 15, 2001 (listing Lasik as a major cause of dry eye); Hovanesian, Shah, and Maloney, *Symptoms of Dry Eye and Recurrent Erosioin Syndrome After Refractive Surgery*, J CATARACT REFRACT SURG., Apr. 2001, 577-84 (noting an incidence of dryness symptoms in 48% of post-Lasik patients).

<sup>34</sup> See David S. Gartry et. al., *Prevention and Management of Complications of Photorefractive Keratectomy*, in Olivia N. Serdarevic, REFRACT SURG: CURRENT TECHNIQUES & MANAGEMENT (1997), p. 91.



condition, which can be permanent, can reduce the blink rate or cause eyelids to open partially during sleep, resulting in greater tear evaporation.

Second, placement of the suction ring at the limbus in order to stabilize the eye prior to creating the flap disrupts the production of goblet cells.<sup>35</sup> Goblet cells are necessary in order to maintain a stable tear film.<sup>36</sup>

Third, the process of cutting the Lasik flap damages many of the nerves that signal the lacrimal glands to produce tears.<sup>37</sup> By one estimate, nearly 70% of corneal nerves are severed during flap creation.<sup>38</sup> Severing of these nerves renders the ocular surface hypesthetic,<sup>39</sup> a problem also known as Lasik-Induced Neurotrophic Epitheliopathy (LINE) or "de-ervation."<sup>40</sup>

Fourth, ablating the cornea with the laser further destroys corneal nerves.

<sup>35</sup> See Diane M. Watson, *Patient Education, Proactive Approach Crucial When Treating Lasik-Induced Dry Eye*, PRIMARY CARE OPTOMETRY NEWS, May 2000.

<sup>36</sup> See R.B. Grene, *Setting New Standards for Lasik Flaps*, OPHTH MAN, April 2001.

<sup>37</sup> See Eric Donnenfeld et. al., *The Effect of Hinge Position on Corneal Sensation Following LASIK*, paper presented at SYMPOSIUM ON CATARACT, IOL, & REFRACT SURG, Apr.-May 2001 (noting that the long posterior corneal nerves enter the eye at 3 and 9 o'clock. A superior hinged flap transects both arms of the neural plexus, while a nasal hinge transects only the temporal arm.). See also Richard L. Lindstrom, M.D., *At Issue: Tears Versus Plugs in Post-Lasik Patients*, OCULAR SURG NEWS, Jun. 1, 2000.

<sup>38</sup> See R.B. Grene, *Setting New Standards for Lasik Flaps*, OPHTH MAN, April 2001.

<sup>39</sup> See Richard L. Lindstrom, M.D., *At Issue: Tears Versus Plugs in Post-Lasik Patients*, OCULAR SURG NEWS, Jun. 1, 2000.

<sup>40</sup> See Rosan Y. Choi, M.D. and Steven E. Wilson, M.D., *LASIK-Induced Dry Eye Can Be Managed*, OCULAR SURG NEWS, Jan. 1, 2001.

The depth of the corneal ablation affects the extent of LINE. According to one study, corneal sensitivity does not recover to the preoperative level even six months after Lasik.<sup>41</sup>

Fifth, the laser alters the corneal curvature, making it difficult to produce and maintain a continuous tear film.<sup>42</sup>

Sixth, because after surgery there is a temporary gap between the corneal flap and the bed, the transfer of cells and other materials may be impeded. Such diffusion barriers affect the recovery of nerve cells and corneal tissues.<sup>43</sup>

The Lasik patient will typically experience dry eyes for at least two months after surgery. Eye drops must constantly be applied, and the individual will often wake up in the middle of the night with severely dry, scratchy eyes that need to be lubricated again.

PLDE sufferers may have to use expensive eye drops indefinitely, and may even need to have punctum plugs inserted into their eyes' drainage ducts in order to reduce the outflow of the few precious tears they have left.<sup>44</sup> In some cases, punctum plugs can cause eye infections, and the only long-term solution to dry eyes becomes permanent cauterization of the tear ducts.

It should be noted that PLDE, although uncomfortable in and of itself,

<sup>41</sup> See Wan-Soo Kim, MD, PhD, Jeong-Sam Kim, MD, *Change in Corneal Sensitivity Following Lasik*, J CATARACT REFRACT SURG, Vol. 25, Mar. 1999.

<sup>42</sup> See R.B. Grene, *Setting New Standards for Lasik Flaps*, OPHTH MAN, April 2001.

<sup>43</sup> See Wan-Soo Kim, MD, PhD, Jeong-Sam Kim, MD, *Change in Corneal Sensitivity Following Lasik*, J CATARACT REFRACT SURG, Vol. 25, Mar. 1999.

<sup>44</sup> The recent proliferation of artificial tear brands such as Theratears, Genteal, and Refresh is more than coincidental with the increase in refractive surgical procedures.

can also lead to reduced visual acuity. The eye's tear film reduces micro-irregularities that naturally occur on the epithelial surface. If this tear film is disrupted, the result is that these normal micro-irregularities are no longer masked by the smooth surface created by the tear film.<sup>45</sup>

## 10. Lasik's Long-Term Risks are Unknown

Ophthalmologists themselves admit that the long-term risks of Lasik are unknown. Peruse ophthalmological literature and you will quickly see how much is being learned about the long-term optical and physiological consequences of Lasik.<sup>46</sup> Most of it isn't positive.

One concern is that with the removal of corneal tissue through Lasik, an individual will not have sufficient corneal thickness left to permit laser ablation for corneal diseases, should these arise later in life. Laser therapies such as Photo-Therapeutic Keratectomy (PTK), which have been developed to resolve ocular problems such as Basement Membrane Dystrophy, can become impossible to

<sup>45</sup> See J. Charles Casebeer, Luis Ruiz, & Stephen Slade, *LAMELLAR REFRACT SURG*, 1996, p.29.

<sup>46</sup> See C. Aras et al, *Retinal Detachment Following Lasik*, *OPHTH SURG. LASERS*, Mar-Apr 2000, pp.121-5 (noting possible association between retinal detachment and Lasik due to increase in intraocular pressure through use of the suction ring to create the flap); Mohamed H. Hosny, M.D., FRCSE et. al., *Posterior Vitreous Detachment Induced by LASIK Procedures*, paper presented at SYMPOSIUM ON CATARACT, IOL, & REFRACT SURG, Apr.-May 2001 (noting that LASIK produces posterior vitreous detachment, especially in higher myopes, due to the acute rise of intraocular pressure during flap creation).

implement if prior Lasik has removed too much corneal tissue.<sup>47</sup>

Another concern is that corneal reshaping through Lasik makes it more difficult for an ophthalmologist to assess the presence of glaucoma. Tonometry measurements, which are taken to determine if a patient has glaucoma, are less accurate when applied on a post-refractive eye due to changes in the cornea's rigidity.<sup>48</sup> One can only wonder how many cases of vision-threatening glaucoma will go undiagnosed among post-refractives in the years to come.

Yet another concern is that the impact from an expanding car air bag can cause severe damage to a cornea already weakened by refractive surgery.<sup>49</sup> Corneal ruptures, which require full-scale corneal transplants, are a well-established phenomenon in auto accidents involving drivers who have undergone a prior form of refractive surgery known as Radial Keratotomy (RK).

## Conclusion

Each of these ten points should be enough to give pause to anyone considering Lasik. Taken as a whole, they raise serious concerns about the wisdom of undergoing this relatively new procedure. These concerns have been raised by some ophthalmologists but have been largely disregarded by most refractive surgeons and the excimer laser

<sup>47</sup> See e.g., Peter S. Hersh and Michael Wagoner, *EXCIMER LASER SURGERY FOR CORNEAL DISORDERS*, 1997.

<sup>48</sup> See M.A. El Danasoury et. al., *Problems Diagnosing Glaucoma After Lasik*, *J REFRACT SURG*, Mar-Apr 2001, Vol. 17(2), pp. 97-104.

<sup>49</sup> See H.L. Lemley et al, *Partial Dislocation of Lasik Flap by Air Bag Injury*, *J REFRACT SURG*, May-Jun 2000, pp.373-4.

industry, which seem more interested in maximizing profits from the Lasik fad rather than looking out for the long-term health of their patients. All too often, well-intentioned refractive surgeons are simply unaware of many of the problems associated with Lasik discussed in this article.

Eyeglasses have been giving people good eyesight for several centuries. Contact lenses have been widely used for three decades and, when cleaned and used properly, have proven themselves to be safe.<sup>50</sup> Lasik has been performed widely for less than five years. ***Does it make sense to risk your eyes on such a new procedure?***

---

<sup>50</sup> There is a documented loss of 2+ lines of Best Corrected Visual Acuity (BCVA) with laser surgery (varying from 100-300 per 10,000), compared to a loss of BCVA of only 1 in 69,000 with contact lenses. See REV CONTACT LENS, supp. to REV OPT, Feb. 2001.

## Common Lasik Complications

**Glare** - A phenomenon in which, after light has bounced off an object and into the eye, it is reflected again in the eye, producing an optical aberration. Consider a sheet of paper being illuminated by a lamp. To a normal eye it will be sharp and clear. For the Lasik patient with this side effect, the sheet of paper will now have a thin ring of white fuzziness around the edges, perhaps extending for an inch or two. Now take this disturbing visual effect from that single sheet of paper and expand it by the several hundred objects in a typical room, and you are looking through a thin white cloud. Many ophthalmologists never inquire about their patients' post-operative glare, and if the patient should mention it, the ophthalmologist will give calming reassurances that it will eventually subside. Instead they focus their diagnostic efforts on simplistic eye chart tests and applaud their patients on how well they can read these charts. They ignore visual complications and instead measure a successful outcome as being able to read the eye chart at the 20/20 level, regardless of the fact that the light bouncing off the eye chart creates a degraded image.



**Example of Post-Lasik Daytime Glare.**

**Halo**es - Glare-related visual aberrations causing a fuzzy, cloudy light surrounding moderately lit objects at night. A red stoplight, for example, will be surrounded by a large red hazy light. Even more disconcerting, haloes fluctuate in size as the pupils naturally expand and contract ever so slightly.



**Post-Lasik Glare of Moon.**



**Pre-Lasik View of Oncoming Traffic.**



**Post-Lasik Haloes with Oncoming Traffic.**




**Post-Lasik Haloes with Traffic Lights.**

**Starbursts** - An optical effect surrounding brightly lit, sharper points of light. The Lasik patient with this symptom will see numerous streaks extending in every direction from a light-emitting object -- like a

July 4 firecracker. What's worse, the light will not be obscured by other objects that may be closer by. As with the glare and haloes, multiply this effect a hundred times and you get an idea of how an otherwise pleasant walk at night down a city street becomes what has been described as a "visual hell," or how the ability to drive at night becomes impaired.

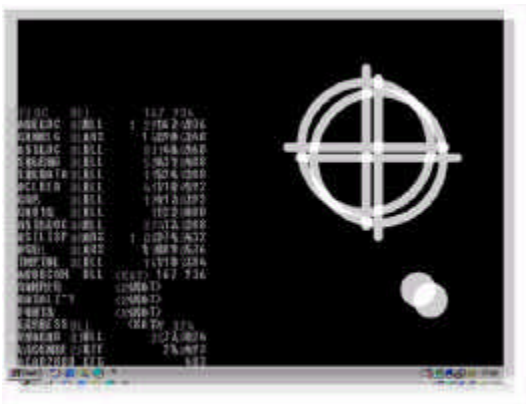


**Post-Lasik Starbursts. The Ability to Drive Safely at Night has been Ruined.**



**Post-Lasik Starbursts.**


**Ghosting** - A faint double vision that occurs when looking at objects in dim light. This visual aberration is most pronounced when watching a movie in a cinema or on television -- every object gives a faint "ghosted" image right beside it. The level of ghosting fluctuates with changing levels of light, which occurs constantly and is quite distracting.



Post-Lasik Ghosting of Computer Screen.



Post-Lasik Ghosting of Eyechart. Refractive Surgeons Consider This to be 20/20 Vision.



Post-Lasik View of Moon with Severe Case of Ghosting.

**Haze** - After the cornea has been ablated by the laser, it begins trying to heal itself. This healing produces microscopic scars that for several weeks produce cloudy vision at all light levels. This symptom generally abates over time but given the unpredictable healing response of each individual, for some the haze is permanent.

**Epithelial Ingrowth** - In some cases following Lasik, epithelial cells will begin growing at the interface between the cornea and the flap after the flap has been re-laid. If the cells do not stop growing, they will begin to cloud and distort vision. In severe cases, epithelial ingrowth can lead to flap melt in which stroma layer cells in the flap are destroyed, resulting in permanent loss of visual acuity. Epithelial ingrowth requires a flap lift to enable the surgeon to clean out the excess cells, and more days of pain and weeks of haze as the re-laid flap heals.

**Corneal Abrasion** - Upon cutting the flap with the microkeratome, or lifting the flap, corneal cells can be dislodged, producing temporary blindness until healing takes place and requiring narcotic pain killers to reduce the severe eye pain that results.

**Dry Eye Syndrome** - Goblet cell disruption and corneal nerve damage decrease tear production, leading to dry eye discomfort and necessitating constant use of eye drops and/or punctum plugs and/or cauterization to occlude the drainage ducts.